



Available online at
SciVerse ScienceDirect
www.sciencedirect.com

Elsevier Masson France
EM|consulte
www.em-consulte.com/en



TECHNICAL NOTE/CLINICAL CASE

Fast and furious: Telecardiology in acute myocardial infarction triage in the emergency room setting

Action, réaction : utilisation de la télécardiologie dès l'entrée aux urgences, à la phase aiguë d'un infarctus du myocarde

**N.D. Brunetti^{a,*}, L. De Gennaro^a, G. Dellegrottaglie^b,
V. Procacci^c, M. Di Biase^a**

^a Cardiology Department, University of Foggia, Foggia, Italy

^b Cardio-On-Line Europe SRL, Bari, Italy

^c Emergency Department, Ospedali Riuniti, Foggia, Italy

Received 29 January 2013; accepted 20 February 2013

KEYWORDS

Emergency room;
Triage;
ST-elevation
myocardial
infarction;
Telecardiology

Summary We present a model of telecardiology ECG triage in cases of acute chest pain. A 61-year-old man with recurrent chest pain, radiating to the neck, was referred to the emergency room (ER) at Foggia University Hospital, Italy, with a red triage code. Due to a large number of red code patients present at the ER all immediately requiring medical examination for suspected acute myocardial infarction (AMI), the patient first underwent ECG triage evaluation with the Cardio Vox P12 telecardiology recorder device by a nurse. The ECG was transmitted to the regional telecardiology hub, where the ECG was immediately read by a cardiologist; signs of an inferior ST-elevation acute myocardial infarction (STEMI) were present. The catheterisation lab was therefore immediately alerted and the patient underwent primary percutaneous coronary intervention (PCI) within thirty minutes of hospitalisation. Therefore, in emergency settings with high-volume work-loads, telecardiology screening may “speed up” STEMI diagnosis and treatment.

© 2013 Elsevier Masson SAS. All rights reserved.

MOTS CLÉS

Urgences ;
Triage ;

Résumé Nous présentons un modèle de télécardiologie ECG de triage en cas de douleur thoracique aiguë. Un homme de 61 ans souffrant de douleurs thoraciques récurrentes, irradiant vers le cou, a été admis aux urgences au centre hospitalier universitaire à Foggia, en Italie, avec un code de triage rouge. En raison d'un grand nombre de patients avec un code rouge aux

* Corresponding author.

E-mail address: nd.brunetti@unifg.it (N.D. Brunetti).

Infarctus du myocarde avec surélévation du segment ST ;
Télécardiologie

urgences, tous nécessitant immédiatement un examen médical pour une suspicion d'infarctus du myocarde aigu, le patient a subi d'abord une évaluation de triage ECG avec le dispositif de télécardiologie Cardio Vox P12 par une infirmière. L'ECG a été transmis au centre régional de télécardiologie, où l'ECG a été lu immédiatement par un cardiologue ; signes d'un infarctus aigu du myocarde avec une surélévation du segment ST en inférieur étaient présents. Le laboratoire de cathétérisme a donc été immédiatement alerté et le patient a subi une intervention coronarienne percutanée primaire dans les trente minutes suivant hospitalisation. Par conséquent, dans le cadre des urgences avec une charge de travail élevée, le dépistage de télécardiologie pourrait « accélérer » le diagnostic et le traitement de l'infarctus du myocarde aigu avec une surélévation du segment ST.

© 2013 Elsevier Masson SAS. Tous droits réservés.

Early triage of patients with acute chest pain is a challenging task in the emergency room (ER) setting: time is crucial as a delay in diagnosis and treatment significantly affects the prognosis [1]. Initial work-up of chest pain in cases of suspected acute myocardial infarction (AMI) is usually based on early ECG examination, possibly obtained in the pre-hospital phase [1]. Nevertheless, obtaining an ECG may not be easy

when the emergency department is crowded or in cases of multiple simultaneous referrals with acute chest pain and suspected acute myocardial infarction. Telecardiology may therefore be helpful in reducing time to ECG, as shown by previous reports [2–4].

A 61-year-old man with recurrent episodes of chest pain, radiating to the neck, was referred to the emergency room

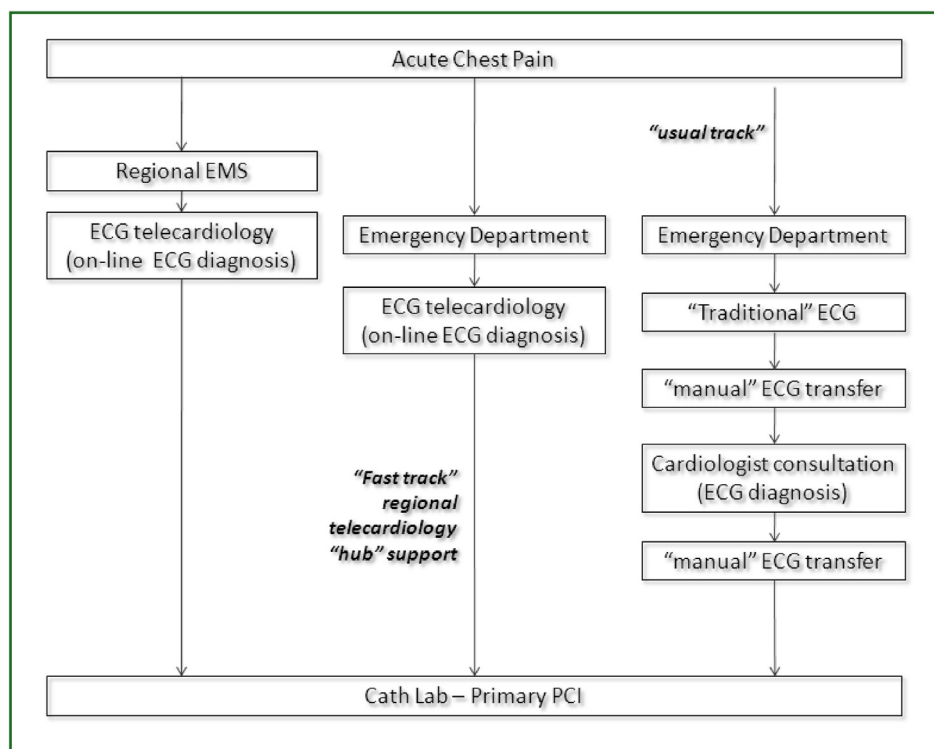


Figure 1. Alternative strategies for ST-elevation acute coronary syndrome diagnosis in patients with acute chest pain currently available in Apulia (Southern Italy) public Health Care Service. Patients calling the emergency medical services (EMS) undergo home ECG examination with telecardiology support (via a single regional telecardiology “hub”). ECG diagnosis of patients admitted to the emergency department (ED) usually requires confirmation by a cardiologist, therefore needing “manual” transfer of the ECG from the ED to the cardiology ward, with consequent delays. ED telecardiology support, avoiding “manual” ECG transfer, reduces time to diagnosis.

Dans les services de soins de santé publique, de la région d'Apulia (Italie du Sud), des stratégies alternatives sont actuellement disponibles en cas de syndrome coronarien aigu avec surélévation du segment ST, chez les patients présentant une douleur thoracique aiguë. Les patients qui appellent le centre 15 sont soumis à l'examen ECG à domicile. L'ECG fait à domicile est pris en charge par l'unique centre régional de télécardiologie. Le diagnostic ECG des patients admis aux urgences nécessite généralement une confirmation par un cardiologue. Actuellement, le transfert de l'ECG des urgences vers le service de cardiologie se fait par personne interposée, ce qui, en matière de pose diagnostique, entraîne une perte de temps. Contrairement, un soutien de télécardiologie réduit le temps de diagnostic en évitant l'échange des documents papiers ECG.

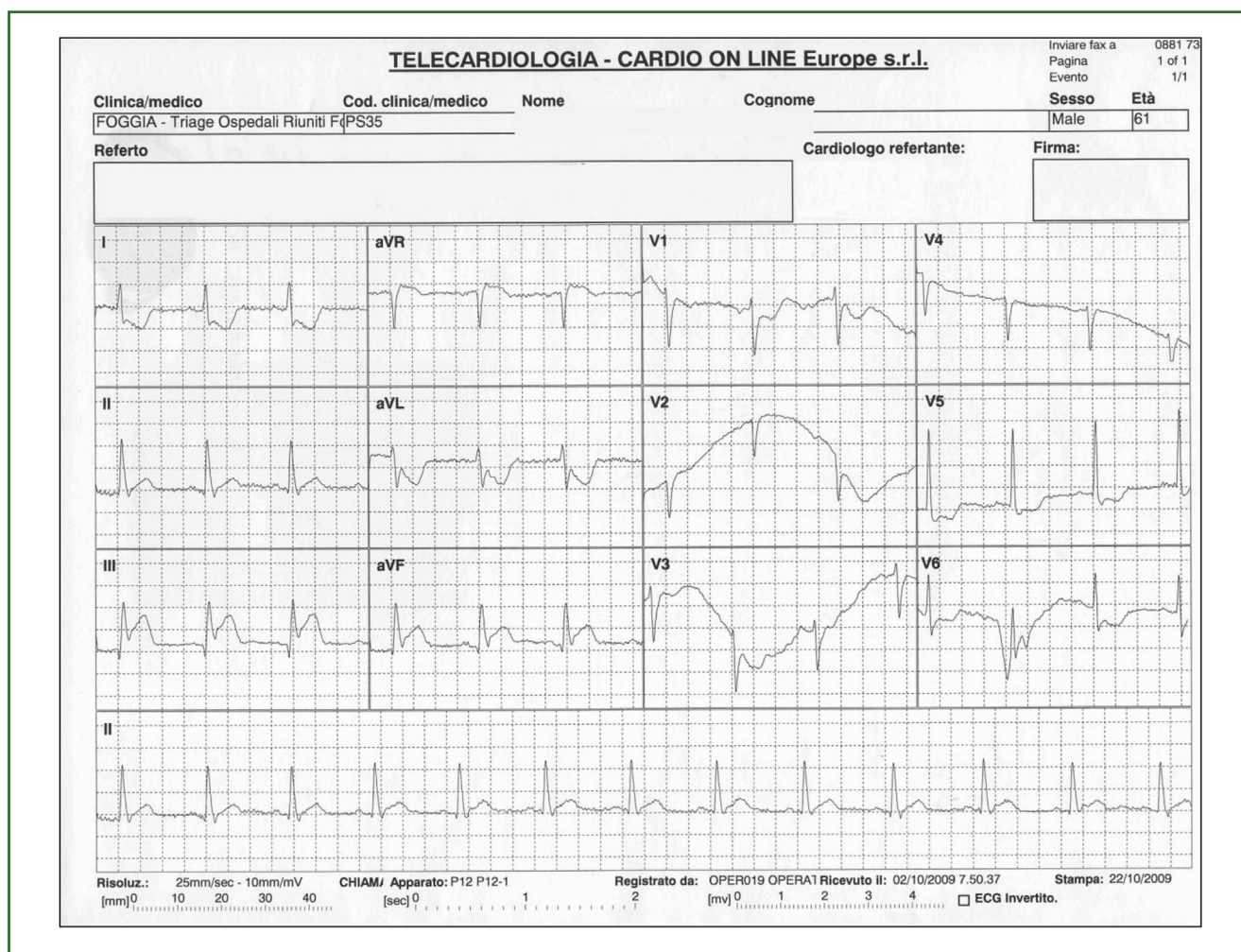


Figure 2. ECG with Cardio Vox P12 device performed at early emergency room triage. The ECG shows ST elevation in the inferior leads and ST-depression in the anterior, DI and aVL leads.

ECG réalisé avec l'appareil Cardio Vox P12 dès l'arrivée aux urgences. L'ECG montre une surélévation du segment ST dans les dérivations inférieures et un sous-décalage de ST dans les dérivations antérieures, en DI et aVL.

of Foggia University Hospital, with a red triage code. Due to a large number of red code patients present in the ER all requiring immediate medical examination for suspected AMI, the patient first underwent ECG triage evaluation with the Cardio Vox P12 telecardiology device by a nurse ("fast track" with telecardiology support: Fig. 1). The device allows the recording of a 12-lead ECG, transmitted by mobile phone to a regional telecardiology hub where a cardiologist immediately provides a report of the ECG findings by fax. The regional telecardiology hub usually supports all emergency crews involved in the "118" public emergency health care service, providing ECG assistance [5].

On the telecardiology ECG, signs of an inferior ST-elevation acute myocardial infarction with specular ST depression were present (Fig. 2). The catheterisation lab was therefore immediately alerted and the patient underwent primary PCI within half an hour since entering the hospital. Coronary angiography showed a stenosis on mid left anterior descending (LAD) coronary artery and an occluded dominant left circumflex (LCX) coronary artery. LCX occlusion was treated with primary stenting with an everolimus eluting stent and symptoms were immediately relieved.

On echocardiogram examination, a left ventricular ejection fraction of 45% with inferior akinesia was present. Peak troponin level during hospitalisation was 171.55 ng/mL. One month later, the patient underwent PCI on LAD. Three-month follow-up was uneventful.

Discussion

Twelve-lead ECG is the gold standard in the diagnosis of ST-elevation acute myocardial infarction; however, ER triage could be delayed when the ECG cannot be promptly reported by qualified personnel within the ER. In this case, an ECG with telecardiology support may be helpful in reducing operational times and time to reperfusion.

ECG recording with the Cardio Vox P12 device usually requires two minutes to acquire the data and two minutes to transmit the data to the telecardiology hub; ECG recording does not usually require the patient to lie down on a bed and can be performed even with the patient sitting.

In emergency settings with high-volume work-loads, telecardiology screening may "accelerate" STEMI diagnosis

and treatment, with consequent positive effects on prognosis. Currently, more than 250 patients with suspected STEMI underwent a “fast track” triage ECG examination as described above in our emergency department.

Disclosure of interest

The authors declare that they have no conflicts of interest concerning this article.

References

- [1] Steg PG, Bonnefoy E, Chabaud S, Lapostolle F, Dubien PY, Cristofini P, et al. Impact of time to treatment on mortality after prehospital fibrinolysis or primary angioplasty. Data from the CAPTIM randomized clinical trial. *Circulation* 2003;108:2851–6.
- [2] Brunetti ND, De Gennaro L, Amodio G, Dellegrottaglie G, Pellegrino PL, Di Biase M, et al. Telecardiology applied to a region-wide public emergency health care service. *J Thromb Thrombolysis* 2009;28:23–30.
- [3] Brunetti ND, De Gennaro L, Amodio G, Dellegrottaglie G, Pellegrino PL, Di Biase M, et al. Telecardiology improves quality of diagnosis and reduces delay to treatment in elderly patients with acute myocardial infarction and atypical presentation. *Eur J Cardiovasc Prev Rehabil* 2010;17:615–20.
- [4] Terkelsen CJ, Lassen JF, Norgaard BL, Gerdes JC, Poulsen SH, Bendix K, et al. Reduction of treatment delay in patients with ST-elevation myocardial infarction: impact of pre-hospital diagnosis and direct referral to primary percutaneous coronary intervention. *Eur Heart J* 2005;26:770–7.
- [5] Brunetti ND, De Gennaro L, Dellegrottaglie G, Amoroso D, Antonelli G, Di Biase M. A regional pre-hospital ECG network with a single tele-cardiology “hub” for public emergency medical service: technical requirements, logistics, manpower and preliminary results. *Telemed J E Health* 2011;17:727–33.